



Video head impulse test in children after cochlear implantation

Video *head* impuls test kod dece nakon kohlearne implantacije

Slobodanka N. Lemajić-Komazec*[†], Zoran S. Komazec*[†], Ljiljana M. Vlaški*[†],
Maja M. Buljčik-Čupić*[†], Slobodan N. Savović*[†], Dunja M. Mihajlović*[‡],
Ivana V. Sokolovac*[†]

University of Novi Sad, *Faculty of Medicine, Novi Sad, Serbia; Clinical Centre of
Vojvodina, [†]Otorhinolaryngology Clinic, Novi Sad, Serbia; Emergency Centre of
Vojvodina, [‡]Department of Anesthesia and Reanimation, Novi Sad, Serbia

Abstract

Background/Aim. Cochlear implantation (CI) is a therapeutic modality that provides a sense of sound to children and adults with profound sensorineural hearing loss or deafness. The aim of this work was to evaluate the lateral semicircular canal function using a high frequency video head impulse test in children after CI. **Methods.** A prospective descriptive study included 28 children (6–17 years old) with profound sensorineural hearing loss and unilateral CI. The control group included 20 healthy children with normal hearing. The measurement of vestibular function of the lateral semicircular canal was performed using video head impulse test. After cochlear implantation, the children underwent the vestibular testing. Values vestibulo-ocular reflex of lateral semicircular canal were measured using the video head impulse test in the children with cochlear implant and the control group. The values of vestibulo-ocular reflex were compared between the group. Also, in the children with CI values of vestibulo-ocular reflex were compared between the non-implanted ear and the ear with the embedded

CI. **Results.** All 28 children with sensorineural hearing loss underwent the placement of CI through cochleostomy at the average age of 4.8 ± 2.92 years. Children with the cochlear implant had a significantly lower vestibulo-ocular reflex gain of the lateral semicircular canal measured by a high frequency video head impulse test compared to the control group of children with normal hearing (T test: $t = 3.714$; $p = 0.001$). However in these children there was no statistically significant difference of vestibulo-ocular reflex gain in the lateral semicircular canal measured in ears with embedded CI and non-implanted ears (T test: $t = 0.419$; $p = 0.677$). **Conclusion.** The values of vestibulo-ocular reflex gain in the lateral semicircular canal evaluated by the video head impulse test are significantly lower in the children with a profound sensorineural hearing loss compared to the children with normal hearing. The CI did not appear to have a negative impact on the lateral semicircular canal.

Key words:

cochlear implantation; head impulse test; semicircular canals; video recording; hearing loss; child; adolescent.

Apstrakt

Uvod/Cilj. Ugradnja kohlearnog implanta (KI) je terapijski modalitet koji obezbeđuje osećaj zvuka kod dece i odraslih sa dubokim senzorneuralnim gubitkom sluha ili gluvoćom. Cilj rada je bio ispitivanje funkcije lateralnog polukružnog kanala upotrebom visokofrekventnog video *head* impuls testa kod dece nakon kohlearne implantacije. **Metode.** U prospektivnu deskriptivnu studiju bilo je uključeno 28 dece (6–17 godina starosti) sa dubokim senzorneuralnim gubitkom sluha i jednostranim KI. Kontrolnu grupu je činilo dvadestoro zdrave dece sa normalnim sluhom. Ispitivanje vestibularne funkcije lateralnog polukružnog kanala je izvršeno visoko frekventnim video *head* impuls testom. Nakon kohlearne implantacije, deca su povrgnuta vestibularnom testiranjem. Vrednosti vestibulo-okularnog refleksa lateralnog polukružnog kanala merene su kod dece sa KI i

kontrolne grupe i međusobno upoređivane. Takođe, kod dece sa KI načinjeno je poređenje vrednosti vestibulo-okularnog refleksa lateralnog polukružnog kanala između neimplantiranog uva i uva sa ugrađenim KI. **Rezultati.** Kod svih 28 dece sa senzorneuralnim gubitkom sluha je načinjena kohlearna implantacija kroz kohleostomu kada su deca bila prosečne starosti $4,8 \pm 2,92$ godine. Deca sa KI su imala signifikantno manju vrednost vestibulo-okularnog refleksa lateralnog polukružnog kanala koji je meren visoko frekventnim video *head* impuls testom u poređenju sa kontrolnom grupom dece sa urednim sluhom (T test: $t = 3,714$; $p = 0,001$). Nije nađena statistički značajna razlika između vrednosti vestibulo-okularnog refleksa lateralnog polukružnog kanala kod ušiju sa ugrađenim KI i neimplantiranih ušiju (T test: $t = 0,419$; $p = 0,677$). **Zaključak.** Vrednost vestibulo-okularnog refleksa lateralnog polukružnog kanala procenjena video *head* impuls testom je značajno niža kod

dece sa dubokim senzorneuralnim gubitkom sluha u poređenju sa decom urednog sluha. Kohlearna implantacija nema negativan uticaj na lateralni polukružni kanal.

Ključne reči:

kohlea, implantacija; head impuls test; polukružni kanali; video snimanje; sluh, gubitak; deca; adolescenti.

Introduction

A cochlear implantation (CI) is a therapeutic modality that provides a sense of sound to children and adults with profound sensorineural hearing loss or deafness^{1,2}. The CI ensures and improves speech development, language perception, cognitive functions, providing children with the ability to develop and understand spoken language. The children with a profound sensorineural hearing loss often have dysfunctions in the vestibular nerve system which plays an important role in the development of motor functions³. There are more studies that investigated the postcochlear implantation vestibular function in adults than in children⁴. The testing of the vestibular function in children after CI is much more difficult than in adults due to a low level of cooperation, lack of reference data, and preoperative vestibular damage associated with sensorineural hearing loss⁵. The CI itself may cause lesions of the vestibular system. The main pathogenetic hypothesis for vestibular dysfunction is the damage of the vestibular receptors during surgical insertion of the electrodes in the cochlea⁶. The video head impulse test (vHIT) is a new tool directed to the evaluation of the semicircular and vertical canals, by a high frequency stimulation, suitable for the pediatric population⁷. The vHIT also provides important information about the function of the semicircular canal by the assessment of vestibulo-ocular reflexes (VOR). The gain, the vHIT output, is calculated by comparing eye and head velocity during the fast horizontal head movements in each of the six semicircular canal planes⁸. The children without vestibular symptoms show an average VOR gain from 0.8 to 1.02⁹.

The aim of this study was to analyze the function of the lateral semicircular canal of the non-implanted ear by the high vHIT in the children after the CI and to compare the results with the control group of children with normal hearing. The second aim of the study was to define whether cochlear implants affected reduction of the VOR gain of the lateral semicircular canal (LSC), ie., compare implanted and non-implanted ears in the children after the CI.

Methods

Sensorineural hearing loss occurs when there is a damage to the cochlea, or to the nerve pathways from the inner ear to the brain. In patients with profound hearing loss threshold is equal or worse than 91 decibels hearing level (dBHL)¹⁰. The present study included 28 children with a profound sensorineural hearing loss. All children underwent the CI. The study was performed in accordance with the ethical guidelines of the Declaration of Helsinki 1975. Specifically, the study was approved by the Institution Review Board (Faculty of Medicine, University of Novi Sad,

Serbia). The parents of children involved in the study signed informed consent form prior to participation in the study.

The inclusion criteria were as follows: children with a profound sensorineural hearing loss under the age of 18 years, unilateral CI, normal temporal bone (normal morpho-functional inner ear) and computed tomography (CT) evaluation. The children with syndromic pathology were not included in the study.

A prospective clinical study was performed at the Clinical Center of Vojvodina, Novi Sad, Serbia, the tertiary health institution and the main hospital of Vojvodina region. All 28 children underwent the CI surgery performed by one of two oto-surgeons; a standard posterior tympanotomy approach was used and electrode insertion was performed through the cochleostomy made anteroinferior to the round window. Each implanted electrode was placed completely, without resistance or complications. Auditory nerve response telemetry was obtained for each child. All embedded implants were Nucleus Freedom cochlear implant speech processors. The cause of hearing loss in all the patients was unknown. The assessment of the vestibular function was made by a battery of the vestibular tests: spontaneous nystagmus test, dynamo-static and orthostatic tests (Romberg, Unterberger) and Dix-Hallpike maneuver for benign paroxysmal positional vertigo. The evaluation of the LSC VOR was done using the high frequency vHIT.

The exclusion criteria were: age over 18 years, children with a profound sensorineural hearing loss and syndromic pathology and the children with the bilateral CI.

The control group included 20 children with normal hearing.

Video head impulse test procedure

The vHIT is a test for assessing the function of LSC, described by Ulmer and Chays in 2005¹¹. The head impulse test is a passive test using high-frequency head movements, amplitude between 10 and 20°, peak 200°/s, used for testing the VOR of each semicircular channel. The anatomical components of the VOR are the semicircular canals in the peripheral vestibular system, vestibular and oculomotor nuclei of the brain stem and the extraocular muscles. The VOR functions to stabilize images on the retinas during head movement by producing eye movements in the direction opposite to head movement. The VOR gain is defined as the ratio of the eye movement response to the head movement stimulus¹². The vHIT was measured using the ICS impulse type 1085 (GN Otometrics, Taastrup, Denmark) with a small high-speed (~250 frames/s) monocular digital infrared video camera on the goggles (weighing 60 g) recording the movements of the right eye. The eye was illuminated by a low level infrared light emitted by the light emitting diode (LED). A small sensor on the goggles measured the head move-

ments. Before starting vestibulo-ocular testing, a brief calibration was performed. The testing was done in a small, sound- and light-proof rooms, in a sitting position, where a child is looking at an eye-level *target* at a minimum distance of 1 m in front of it, and activation of the convergence system may interfere with the VOR¹². The head movement velocity is measured by a sensor on the goggles, and high-speed camera was incorporated for superior eye tracking. Each head movement and eye response are simultaneously shown on the screen, so the clinician could see whether the stimulus and the response were adequate¹³. The horizontal vHIT stimulus consisted of the rapid, passive and unpredictable head movements in both directions (the clinician placed both hands on the head of the patients, and rotated the head abruptly and unpredictably to the right or left, 20 impulses at random to the right and 20 to the left), whereas every impulse was very short¹⁴. Some authors believe that passive impulses are much more sensitive in the identification of the VOR deficit¹⁵. The parameters evaluating the LSC VOR are the mean gain (the ratio of the eye movement response to the head movement stimulus).

Statistical data analysis

The statistical data analysis was performed using the software package Statistical Package for Social Sciences – SPSS 21. The quantitative variables were presented as the mean values (arithmetic mean) and the measures of variability (range of values, standard deviation) and qualitative variables by using frequencies and percentages. The comparison of quantitative variables between the two groups was performed using the Student's *t*-test. The differences in frequency of the qualitative variables were assessed using χ^2 -test.

Results

This study included a cohort of 28 children with the CI, mean age 12.9 ± 3.09 years (range from 6 to 17 years). On ave-

rage, the children underwent the CI at the age of 4.8 ± 2.9 years. All children were implanted unilaterally. The right ear was implanted in 18, and left in 10 children. All patients underwent the preoperative CT of the temporal bone, showing normal morphology of the inner ear, and the cause of deafness was unknown. The control group included 20 children with normal hearing, average age 10.7 ± 4.2 years (from 4 to 16 years).

We found that the results of the vestibular function tests, defined as spontaneous nystagmus, oto-neurological tests, Dix Hallpike maneuver for benign paroxysmal positional vertigo, were normal in the children with CI and the control group (Table 1). There was no significant difference in the presence of vertigo in the children with the CI and the children in the control group (Table 1). However, the children with the CI had the significantly lower values of the LSC VOR gain vHIT compared to the control group: 0.89 ± 0.18 vs. 1.04 ± 0.09 , respectively ($t = 3.714$; $p = 0.001$) (Figure 1).

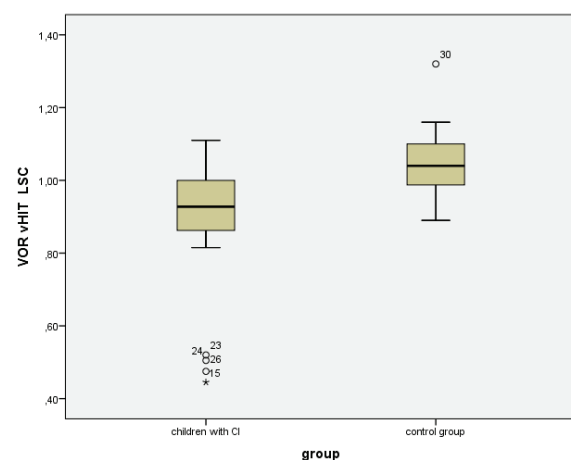


Fig. 1 – Values of the lateral semicircular canal (LSC) vestibulo-ocular reflexes (VOR) gain using video head impulse test (vHIT) between the children with cochlear implantation (CI) and the control group.

Table 1

The investigated parameters in the group of children with the cochlear implantation (CI) in comparison to the control group

Variables	Children with CI (n = 28)	Control group (n = 20)	<i>p</i>
Age (years), mean \pm SD	12.9 ± 3.09	10.7 ± 4.2	0.042
Sex (male/female), n (%)	11 (39.3)/17(60.7)	13 (65)/7 (35)	0.079
VOR gain vHIT	0.89 ± 0.18	1.04 ± 0.09	0.001
Vestibular function tests			
vertigo (positive/negative), n (%)	1(3.6)/27 (96.4)	0 (0)/20 (100)	1.00
spontaneous nystagmus (positive/negative), n (%)	0 (0)/28 (100)	0 (0)/20 (100)	–
Romberg's test (positive/negative), n (%)	0 (0)/28 (100)	0 (0)/20 (100)	–
Unterberger's test (positive/negative), n (%)	0 (0)/28 (100)	0 (0)/20 (100)	–
Dix Hallpike maneuver test (positive/negative), n (%)	0 (0)/28 (100)	0 (0)/20 (100)	–
supine roll test (positive/negative), n (%)	0 (0)/28 (100)	0 (0)/20 (100)	–
deep head hanging maneuver (positive/negative), n (%)	0 (0)/28 (100)	0 (0)/20 (100)	–

SD – standard deviation; VOR – vestibulo-ocular reflex; vHIT – video head impulse test; *p* – statistical significance.

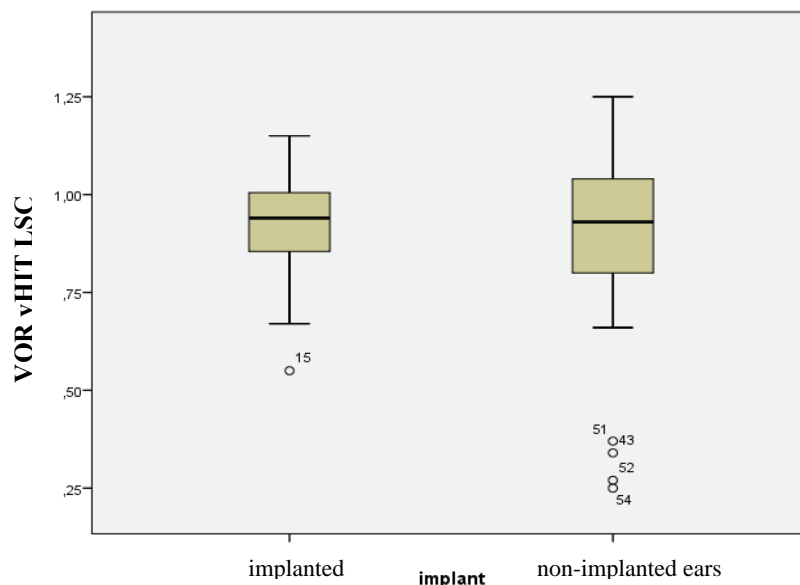


Fig. 2 – Values of the lateral semicircular canals (LSC) vestibulo-ocular reflexes (VOR) gain using video head impulse test (vHIT) between implanted and non-implanted ears, in children with cochlear implantation.

A statistically significant difference was not obtained ($t = 0.419$; $p = 0.677$) for the values of the VOR gain vHIT between the implanted (0.91 ± 0.14) and non-implanted ears (0.86 ± 0.26) (Figure 2).

Discussion

The mechanisms of vestibular function damage after the CI are still unknown. However, they may be related to a number of etiological factors as well as trauma caused by electrode insertion, labyrinthitis, perilymphatic postoperative fistula, endolymphatic hydrops, intraoperative perilymph gusher, electrical stimulation of the vestibular implant, benign paroxysmal positional vertigo¹⁶⁻¹⁹. It has been reported that a postoperative vestibular damage after the CI occurs in 6%–80% of adult patients, and in 9%–50% of implanted children^{4, 20, 21}. The post-mortem histological examination of the cochlea of the temporal bone, showed that the CI leads to the structural damage of the inner ear, and in particular cochlear hydrops caused by endolymphatic flow obstruction and the posterior labyrinth²². The impact of the CI on the postoperative vestibular function is difficult to assess if it was not preoperatively evaluated. The relevant literature describes the vestibular dysfunctions in 30%–70% of the children with hearing loss⁴. Although the CI affects the vestibular function, after the implantation, children show rapid compensation of the sensory deficit and therefore the vestibular damage may not be detected at all²¹. This is the reason for discrepancy between the subjective symptoms and the results of vestibular tests, which are objective.

The vestibular function tests are more difficult to perform in children than in adults, no matter if children have the CI or not. So far, only one study evaluated the vestibular function (LSC VOR gain) in children after the CI using vHIT. Our results showed that the LSC VOR gain evaluated by the vHIT of the non-implanted ears in the children with

sensorineural hearing loss was significantly lower compared to the control group. These data can be explained by the fact that in congenital bilateral sensorineural hearing loss, the vestibular dysfunction is common, and that it was present before surgery as well. Nassif et al.⁵ published the first paper on the examination of the LSC high frequency VOR using the vHIT in children after the bilateral CI and presented the different results. They found that the LSC high frequency VOR gain in 16 children with the unilateral and bilateral CI did not differ between the non-implanted ears in children with the CI and profound sensorineural hearing loss, and the control group of children with normal hearing. Another important finding of this study is that there was no statistically significant difference in the VOR gain high frequency vHIT between the implanted and non-implanted ears in the unilaterally implanted children with profound sensorineural hearing loss. The same conclusions were reported by other authors, using the low-frequency caloric stimulation test in adults after the CI²³⁻²⁵. In their study on children after the CI, Nassif et al.⁵ also found that there were no statistically significant differences of the LSC VOR gain between the implanted and non-implanted ears. Migliaccio et al.²⁶ established that the significant vestibular dysfunctions after the CI were very rare. Wolter et al.²⁷ reported different results; namely, the children with the CI showed significantly more LSC function abnormalities than the children without CI.

According to Thierry et al.²¹, 50% of children had normal bilateral vestibular responses after the CI, whereas the other 50% showed various kinds of anomalies: unilateral or bilateral vestibular dysfunction, 19% of children had asymmetry of vestibular function on the side of CI, while one third of them had abnormal findings in the contralateral ear. Jutila et al.²⁸ used a motorized head impulse test after the CI and found a significantly lower LSC gain only in 4 patients out of 44 adults with the CI in the early and in 2 patients in the late postoperative period; they concluded that

high-frequency loss of vestibular function or vestibular symptoms are rare, but possible after the CI. Batuescas-Caletrio et al.¹³ reported that one third of adult patients with the CI had changes in the LSC gain. Vestibular function after CI was examined by the HIT only in 4 studies²⁹. Basta et al.³⁰ found no loss of saccular function by the HIT after the CI. It is assumed that persistent postsurgical instability may be due to a possible co-activation of the inferior vestibular nerve by electrical stimulation.

The literature data show many controversies regarding the impact of surgical approach on the CI, through the round window, or cochleostomy, on the vestibular function³¹. Some authors believe that electrode insertion through the round window is less traumatic than through cochleostomy³¹. Although in

our study the CI was performed through cochleostomy, it showed no negative effects on the vestibular function.

Conclusion

The evaluation of the vestibular function of lateral semicircular canal by the video head impuls test in children is non-invasive and objective method. It is hard to explain the impact of cochlear implant on the vestibular function and findings of the vestibular tests do not correlate with subjective symptoms. The results of this study imply that the cochlear implant has no effect on reduction of the LSC measured by the high frequency video head impuls test. The cochlear implant is a safe surgical procedure with a low complication rate.

R E F E R E N C E S

1. *Cysneiros HR, Leal MC, Lucena JA, Muniz LF.* Relationship between auditory perception and vocal production in cochlear implantees: A systematic review. *Codas* 2016; 28(5): 634–9. (Portuguese, English)
2. *Vila PM, Hullar TE, Buchman CA, Lieu JE.* Analysis of Outcome Domains in Adult Cochlear Implantation: A Systematic Review. *Otolaryngol Head Neck Surg* 2016; 155(2): 238–45.
3. *Inoue A, Iwasaki S, Ushio M, Chihara Y, Fujimoto C, Egami N, et al.* Effect of vestibular dysfunction on the development of gross motor function in children with profound hearing loss. *Audiol Neurootol* 2013; 18(3): 143–51.
4. *Jacot E, van den Abbeele T, Debre HR, Wiener-Vacher SR.* Vestibular impairments pre- and post-cochlear implant in children. *Int J Pediatr Otorhinolaryngol* 2009; 73(2): 209–17.
5. *Nassif N, Balzanelli C, Redaelli de Zinis LO.* Preliminary results of video Head Impulse Testing (vHIT) in children with cochlear implants. *Int J Pediatr Otorhinolaryngol* 2016; 88: 30–3.
6. *Tien H, Linthicum FH.* Histopathologic changes in the vestibule after cochlear implantation. *Otolaryngol Head Neck Surg* 2002; 127(4): 260–4.
7. *Hamilton SS, Zhou G, Brodsky JR.* Video head impulse testing (VHIT) in the pediatric population. *Int J Pediatr Otorhinolaryngol* 2015; 79(8): 1283–7.
8. *Patterson JN, Bassett AM, Mollak CM, Honaker JA.* Effects of Hand Placement Technique on the Video Head Impulse Test (vHIT) in Younger and Older Adults. *Otol Neurotol* 2015; 36(6): 1061–8.
9. *Hülse R, Hörmann K, Servais JJ, Hülse M, Wenzel A.* Clinical experience with video Head Impulse Test in children. *Int J Pediatr Otorhinolaryngol* 2015; 79(8): 1288–93.
10. *Clark JG.* Uses and abuses of hearing loss classification. *ASHA* 1981; 23(7): 493–500.
11. *Ulmer E, Chays A.* Curthoys and Halmagyi Head Impulse test: an analytical device. *Ann Otolaryngol Chir Cervicofac* 2005; 122(2): 84–90. (French)
12. *Albabib SF, Saliba I.* Video head impulse test: a review of the literature. *Eur Arch Otorhinolaryngol* 2017; 274(3): 1215–22.
13. *Batuecas-Caletrio A, Klumpp M, Santacruz-Ruiz S, Benito Gonzalez F, Gonzalez Sánchez E, Arriaga M.* Vestibular function in cochlear implantation: Correlating objectiveness and subjectiveness. *Laryngoscope* 2015; 125(10): 2371–5.
14. *McGarvie LA, Macdougall HG, Halmagyi GM, Burgess AM, Weber KP, Curthoys IS.* The Video Head Impulse Test (vHIT) of Semicircular Canal Function: Age-Dependent Normative Values of VOR Gain in Healthy Subjects. *Front Neurol* 2015; 6: 154.
15. *Black RA, Halmagyi MG, Thurtell MJ, Todd MJ, Curthoys IS.* The active head-impulse test in unilateral peripheral vestibulopathy. *Arch Neurol* 2005; 62(2): 290–3.
16. *Krause E, Louza JPR, Hempel J, Wechtenbruch J, Rader T, Gürkov R.* Prevalence and characteristics of preoperative balance disorders in cochlear implant candidates. *Ann Otol Rhinol Laryngol* 2008; 117(10): 764–8.
17. *O'Leary MJ, Fayad J, House WF, Linthicum FH.* Electrode insertion trauma in cochlear implantation. *Ann Otol Rhinol Laryngol* 1991; 100(9 Pt 1): 695–9.
18. *Kubo T, Yamamoto K, Iwaki T, Doi K, Tamura M.* Different forms of dizziness occurring after cochlear implant. *Eur Arch Otorhinolaryngol* 2001; 258(1): 9–12.
19. *Cohen NL, Hoffman RA.* Complications of cochlear implant surgery in adults and children. *Ann Otol Rhinol Laryngol* 1991; 100(9 Pt 1): 708–11.
20. *Filipo R, Patrizi M, La Gamma R, D'Elia C, La Rosa G, Barbara M.* Vestibular impairment and cochlear implantation. *Acta Otolaryngol* 2006; 126(12): 1266–74.
21. *Thierry B, Blanchard M, Leboulanger N, Parodi M, Wiener-Vacher SR, Garabedian E, et al.* Cochlear implantation and vestibular function in children. *Int J Pediatr Otorhinolaryngol* 2015; 79(2): 101–4.
22. *Handzel O, Burgess BJ, Nadol JB.* Histopathology of the peripheral vestibular system after cochlear implantation in the human. *Otol Neurotol* 2006; 27(1): 57–64.
23. *Cushing SL, Gordon KA, Rutka JA, James AL, Papsin BC.* Vestibular end-organ dysfunction in children with sensorineural hearing loss and cochlear implants: An expanded cohort and etiologic assessment. *Otol Neurotol* 2013; 34(3): 422–8.
24. *Cushing SL, Papsin BC, Rutka JA, James AL, Gordon KA.* Evidence of vestibular and balance dysfunction in children with profound sensorineural hearing loss using cochlear implants. *Laryngoscope* 2008; 118(10): 1814–23.
25. *Cushing SL, Chia R, James AL, Papsin BC, Gordon KA.* A test of static and dynamic balance function in children with cochlear implants: The vestibular olympics. *Arch Otolaryngol Head Neck Surg* 2008; 134(1): 34–8.
26. *Migliaccio AA, Della Santina CC, Carey JP, Niparko JK, Minor LB.* The vestibulo-ocular reflex response to head impulses rarely decreases after cochlear implantation. *Otol Neurotol* 2005; 26(4): 655–60.
27. *Wolter NE, Gordon KA, Papsin BC, Cushing SL.* Vestibular and Balance Impairment Contributes to Cochlear Implant Failure in Children. *Otol Neurotol* 2015; 36(6): 1029–34.

28. *Juttila T, Aalto H, Hirvonen TP.* Cochlear implantation rarely alters horizontal vestibulo-ocular reflex in motorized head impulse test. *Otol Neurotol* 2013; 34(1): 48–52.
29. *Abouzayd M, Smith PF, Moreau S, Hittier M.* What vestibular tests to choose in symptomatic patients after a cochlear implant?, A systematic review and meta-analysis. *Eur Arch Otorhinolaryngol* 2017; 274(1): 53–63.
30. *Basta D, Todt I, Goepel F, Ernst A.* Loss of saccular function after cochlear implantation: The diagnostic impact of intracochlear electrically elicited vestibular evoked myogenic potentials. *Audiol Neurootol* 2008; 13(3): 187–92.
31. *Todt I, Basta D, Ernst A.* Does the surgical approach in cochlear implantation influence the occurrence of postoperative vertigo? *Otolaryngol Head Neck Surg* 2008; 138(1): 8–12.

Received on April 27, 2017.

Accepted on June 27, 2017.

Online First July, 2017.